



## Paracentral Acute Middle Maculopathy Post Implantable Collamer Lens Implantation

Lulwa AlMatoq<sup>1\*</sup>, Aseel AlKandari<sup>2</sup>, Jamal Behbehani<sup>3</sup>, Raed Behbehani<sup>4</sup> and Alaa AlAli

<sup>1</sup>Senior Ophthalmologist, Retina Division, Al Bahar Eye Center, Ibn Sina Hospital, Al Jahra Hospital, Kuwait

<sup>2</sup>Language Instructor – ELD CEA Coordinator, Kuwait

<sup>3</sup>Ophthalmology Consultant at Cosmo Lasik Eye Clinic, Kuwait

<sup>4</sup>Al-Bahar Ophthalmology Center, Ibn Sina Hospital, P.O Box 1180, Kuwait City, Kuwait

<sup>5</sup>Vitreoretinal Service, Department of Ophthalmology, Ibn Sina Hospital, Kuwait City, Kuwait

*Citation: NLulwa AlMatoq, Aseel AlKandari, Jamal Behbehani, Raed Behbehani, Alaa AlAli (2025) Paracentral Acute Middle Maculopathy Post Implantable Collamer Lens Implantation. J of Opt Res Therapy 1(1), 1-10. WMJ-JORT -105*

**\*Corresponding author:** Lulwa AlMatoq, Senior Ophthalmologist, Retina Division, Al Bahar Eye Center, Ibn Sina Hospital, Al Jahra Hospital, Kuwait.

**Submitted:** 11.11.2025

**Accepted:** 17.11.2025

**Published:** 26.11.2025

### Introduction

Paracentral Acute Middle Maculopathy (PAMM) was first described in 2013 as a clinical entity based on optical coherence tomography (OCT) findings [1,2]. In the acute phase, PAMM is characterized by a hyperreflective band confined to the inner nuclear layer (INL) of the retina secondary to an ischemic event in the intermediate and deep capillary plexus [2]. As a result, INL atrophy develops later on in the disease course [1,3,4].

The clinical presentation of PAMM is unilateral or bilateral sudden onset central/ paracentral scotoma with visual acuity ranging from 20/20 to hand motion (HM) [4]. Deep greyish retinal lesions may be seen on fundus examination, although normal fundus appearance has also been reported [4].

PAMM can be idiopathic or secondary to various retinal and systemic microvascular diseases. Some identified etiologies include, local retinal vascular events such as retinal arterial and venous occlusions, diabetic retinopathy, hypertensive retinopathy, sickle cell retinopathy, Purtscher's retinopathy, and retinal vasculitis [3]. Other etiologies include; migraine, medications such as excessive caffeine intake, vasopressors, and oral contraceptive pill (OCP), a viral prodrome, and following intraocular surgeries due to sudden rise in intraocular pressure (IOP) [2-5].

Implantable collamer lens (ICL), is a single piece refractive phakic posterior chamber intraocular lens with a central port that has been commercially available since 2011 [6]. ICL is used to correct high refractive errors that cannot be corrected with the standard refractive surgeries.

In this case report, we present a case of PAMM in a young, healthy male who underwent ICL implantation to correct high myopia. To our knowledge, this is the first case of PAMM that is reported post ICL implantation.

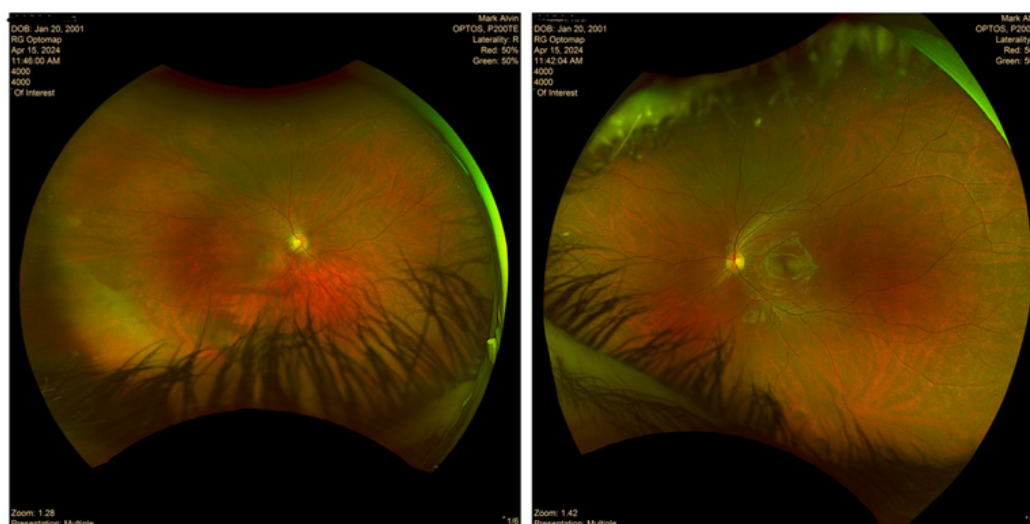
### Case Presentation

A 23-year-old healthy male referred to the retina clinic with sudden onset unilateral central scotoma, immediately after removing the eye patch on post-operative day one of right eye icl implantation for anisometropic myopia. His best-corrected visual acuity was 20/300 in the right eye and 20/20 in the left eye.


Pre-operative refraction was -9.00 OD and -0.75 OS with a best-corrected visual acuity (BCVA) of 20/25 OD and 20/20 OS. Axial length was 27.59mm OD and 23.81mm OS. The rest of his pre-operative examination was normal including dilated fundus examination.

The patient underwent right ICL implantation under retrobulbar anesthesia, a total of 5 cc of 2% lidocaine with 0.5% marcaine without hyaluronidase was used. Intracameral fphenylephrine was used to achieve maximum pupillary dilation. Viscoelastic (Healon) was used during ICL implantation and was removed using a technique where he pressurizes the eye with viscoelastic to “burp” the retained sub-ICL viscoelastic to avoid any post-operative pressure spikes. On the first post-operative day upon removal of the eye patch, the patient immediately noticed a black central scotoma.

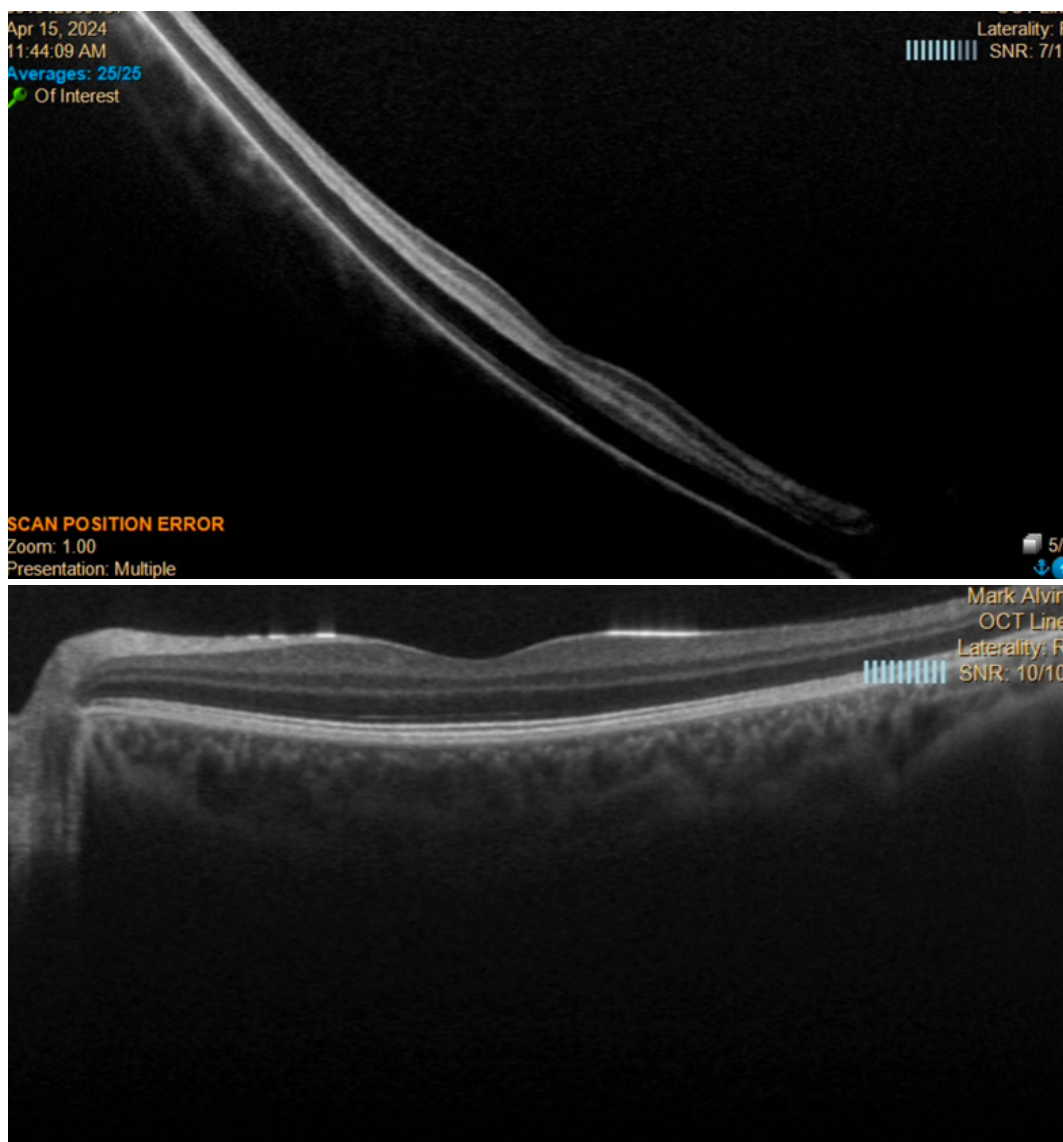
His BCVA was 20/300 OD and 20/20 OS. There was a relative afferent pupillary defect OD. Slit lamp examination was unremarkable and showed a well-centered ICL. Intraocular pressure was 14mmHg OU. Dilated fundus examination of the right eye showed loss of the foveal reflex with greyish patches in the perifoveal region (figure1). Fundus examination of the left eye was unremarkable. Amsler Grid testing revealed large central scotoma in right eye. (figure 2). OCT was obtained which showed a hyper-reflective band in the INL with normal outer retinal layers and normal foveal contour in the right eye (figure 3). Left eye OCT was unremarkable. Compared to the left eye, the right eye showed enlarged FAZ on OCTA. (figure 4)



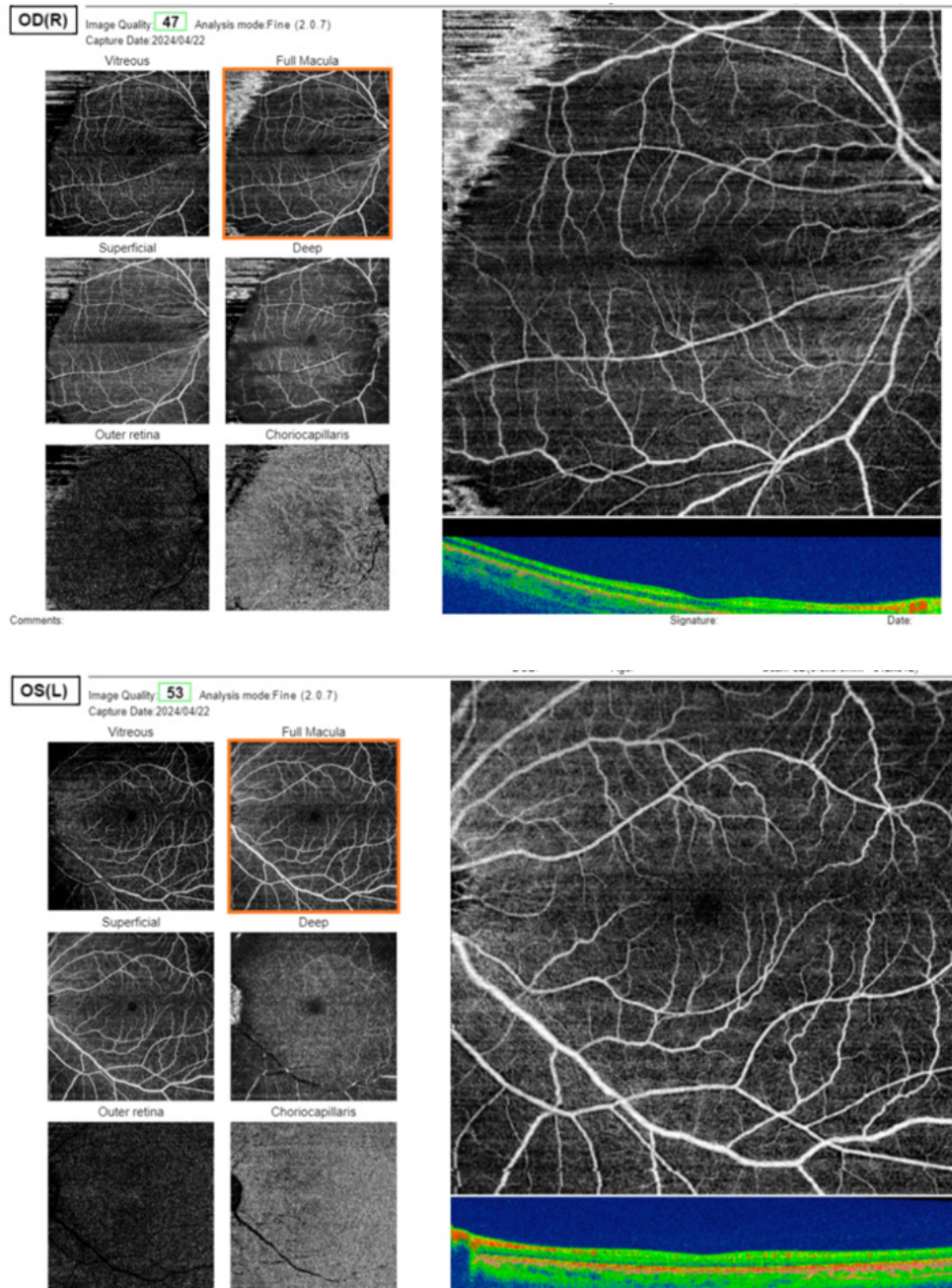
**Figure 1:** Optos Ultra-Wide Field image of right eye showing loss of the foveal reflex with greyish patches (red arrow) in the perifoveal region and mild temporal pallor (black arrow) of the optic disc. Left fundus image is unremarkable.



**Figure 2:** Amsler Grid of Right eye showing central scotoma subjectively. Normal Amsler grid in Left eye.



**Figure 3:** OCT of right eye showing a hyper-reflective band in the INL with normal outer retinal layers and normal foveal contour in the right eye. Left eye OCT is normal.



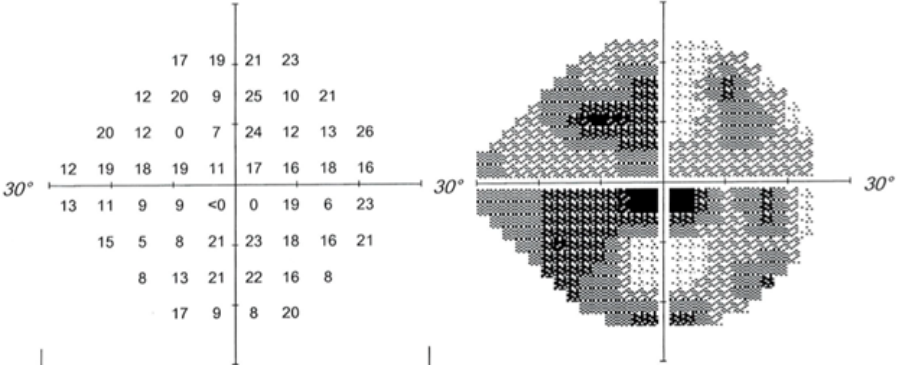
**Figure 4:** OCT-A showing enlarged FAZ in right eye. Normal OCT-A in left eye.

The final diagnosis in this patient is PAMM. No viral prodrome was noted. The patient was not taking any medications, nonetheless he was consuming excessive caffeine intake of around 600mg daily from energy drinks.

The patient was followed up at 1,2, and 3 months and subjectively reported mild improvement of vision, however his BCVA in the affected eye remained the same. Visual field 24 - 4 showed central scotoma with global depression in right eye. (figure 5) OCT showed diffuse ganglion-cell/inner-plexiform (GCIPL) loss and severe thinning of the retinal nerve fiber layer RNFL. (figure 6)

**OD Single Field Analysis** **Central 24-2 Threshold Test**

Fixation Monitor:	Off	Stimulus:	III, White	Date:	Apr 15, 2024
Fixation Target:	Central	Background:	31.5 asb	Time:	9:25 AM
Fixation Losses:	0/0	Strategy:	SITA Faster	Age:	23
False POS Errors:	3%	Pupil Diameter:			
False NEG Errors:	8%	Visual Acuity:			
Test Duration:	04:15	Rx:	+0.00 DS		
Fovea:	Off				



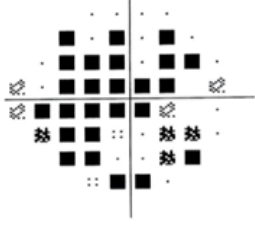
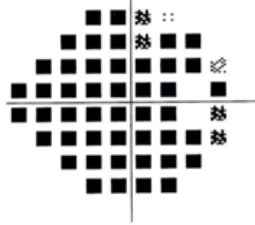
-13-11	-8	-7
-20-12-23	-7	-22-10
-11-20-33-26	-9	-20-19-6
-18-13-16-15-23	-18-18	-16
-17-21-24-26-37	-35-14	-9
-17-28-25-13	-11-16-16-11	
-24-19-12	-10-17-24	
-14-22	-24-12	

Total Deviation

-3	-1	2	4				
-10	-2	-13	3	-11	0		
-1	-10	-23-16	1	-10	-9	4	
-8	-3	-6	-5	-13	-8	-8	-6
-7	-11	-14	-16	-27	-25	-4	1
-7	-18	-15	-3	-1	-6	-6	-1
-14	-9	-2	0	-7	-14		
-4	-12	-13	-2				

Pattern Deviation

GHT: Outside Normal Limits  
 VFI: 49%  
 MD24-2: -18.49 dB P < 0.5%  
 PSD24-2: 7.62 dB P < 0.5%



:: P < 5%  
 \* P < 2%  
 \* P < 1%  
 ■ P < 0.5%

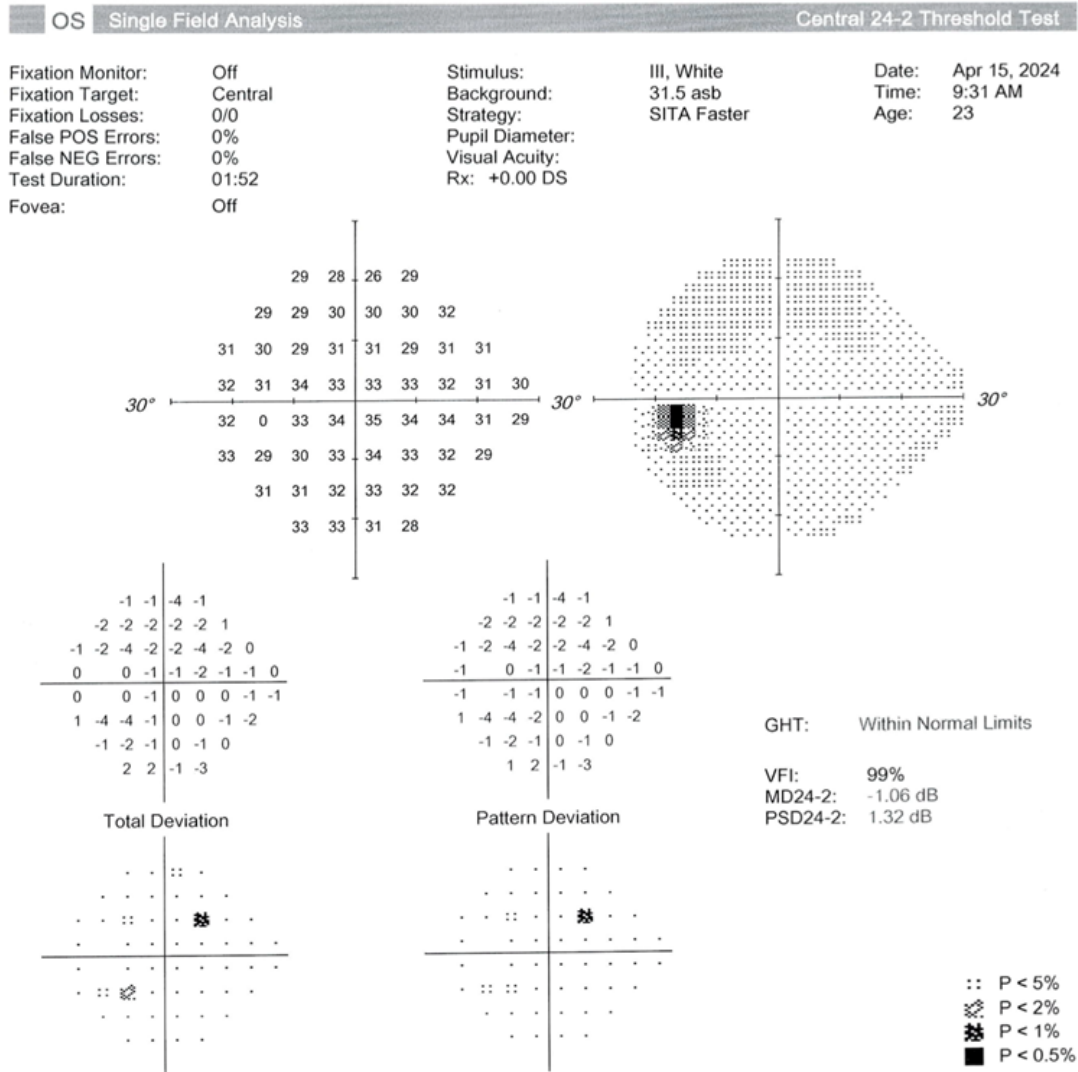
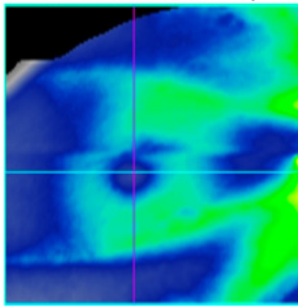


Figure 5: Visual Field 24-4 showed central scotoma with global depression in right eye. Normal Left eye.

Macula Thickness OU: Macular Cube 512x128

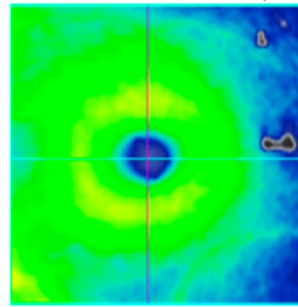
OD ● ● OS

OD ILM-RPE Thickness Map



Fovea: 224, 72

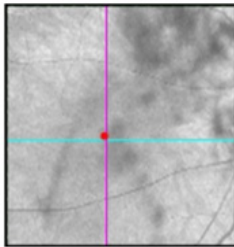
OS ILM-RPE Thickness Map



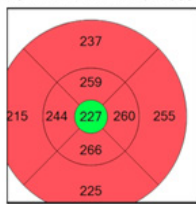
Fovea: 236, 66



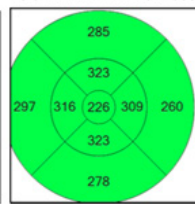OD OCT Fundus



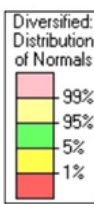
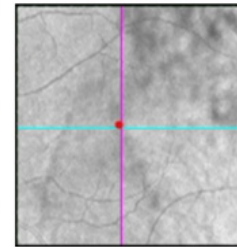
OD ILM-RPE Thickness



OS ILM-RPE Thickness



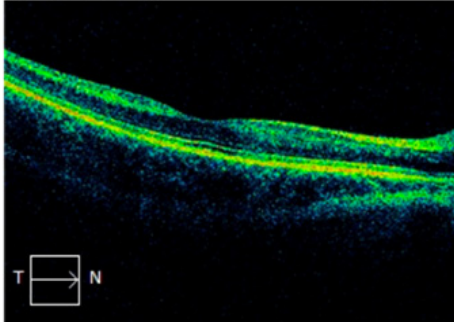
OS OCT Fundus



ILM - RPE	OD	OS
Thickness Central Subfield (µm)	227	226
Volume Cube (mm <sup>3</sup> )	8.2	10.1
Thickness Avg Cube (µm)	227	280

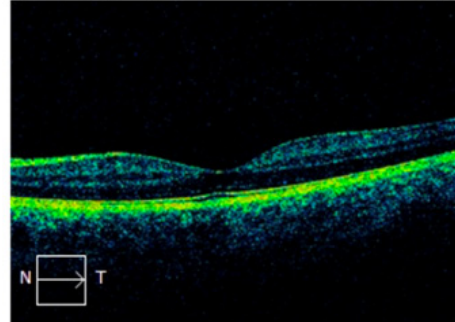
OD Horizontal B-Scan

BScan: 72

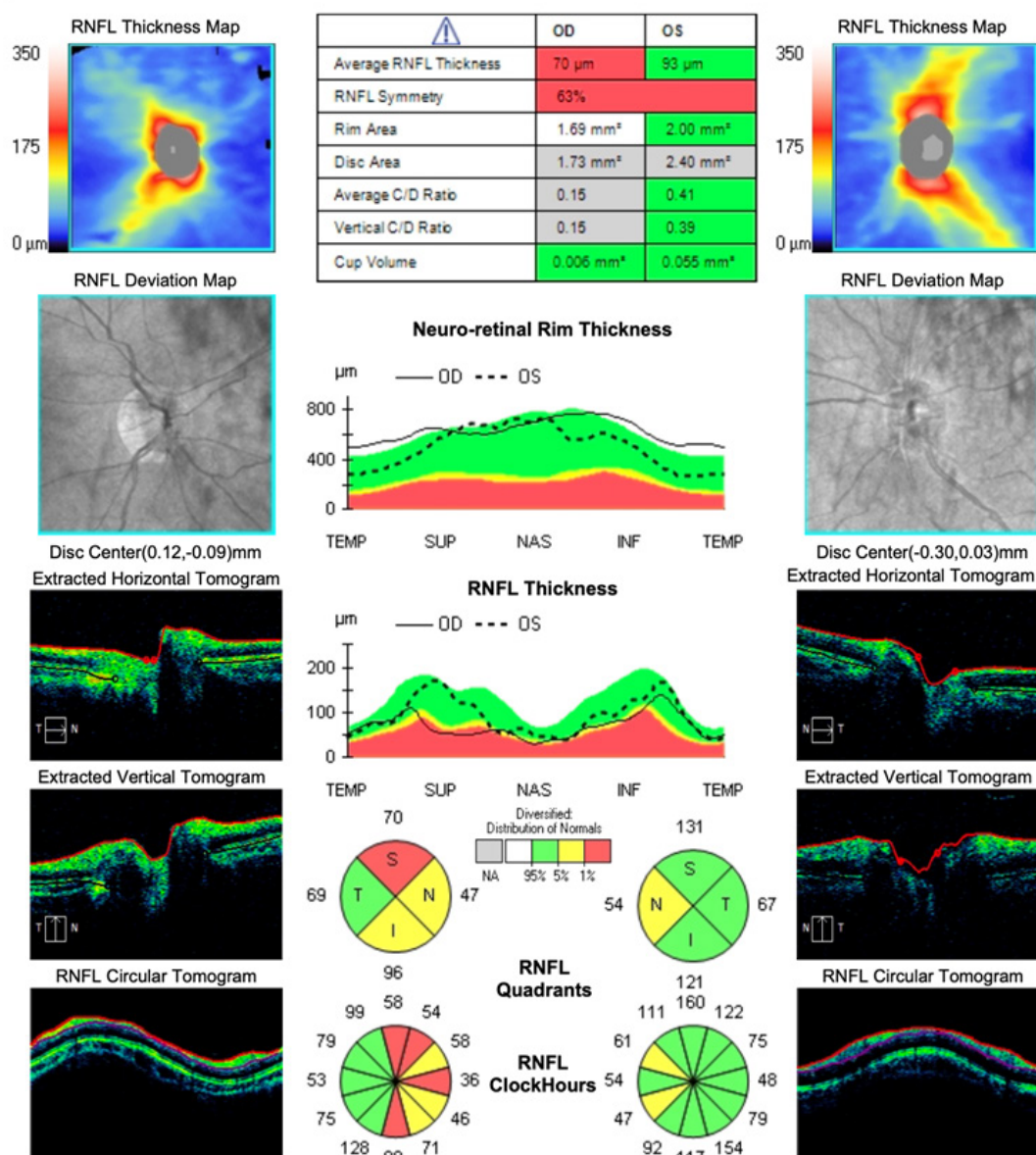


OS Horizontal B-Scan

BScan: 66



ONH and RNFL OU Analysis: Optic Disc Cube 200x200 OD ● OS



**Figure 6:** OCT showing diffuse ganglion-cell/inner-plexiform (GCIPL) loss and severe thinning of the retinal nerve fiber layer RNFL in right eye.

**Discussion**

PAMM is an OCT based-diagnosis characterized as a hyperreflective band in the INL that results from compromised blood flow to the deep retinal layer [2,4]. This ischemic event often leads to variable loss of vision in the affected eye [2,3,5].

Multiple etiologies have been identified in reported cases of PAMM. We can divide them into intrinsic and extrinsic. Intrinsic causes include systemic and retinal vascular diseases, diabetes, sickle cell, and purtschers’ retinopathy [4]. None of these factors were identified in our patient.

Some extrinsic risk factors include excessive caffeine intake, medications including vasopressors and OCP, orbital compression injuries, and viral prodrome [4]. Several plausible extrinsic risk factors were identified in our patient. The patient reported high daily caffeine intake of 600 milligrams through energy drinks. In addition, the patient received intra-cameral phenylephrine to achieve maximum pupillary dilation for his planned

ICL implantation. Vasopressors lead to exacerbation of retinal capillaries vasoconstriction, increase in arterial stiffness, and further rise in arterial blood pressure with transient capillary vascular occlusions [7].

Post-operative intraocular pressure spikes may have compromised the vascular supply to the deep retinal layer which resulted in subsequent ischemia. PAMM has also been reported post cataract surgery, pterygium excision, and PPV [3,5, 8-10]. All cases described in literature underwent local anesthesia (peribulbar/subtenon) and therefore [10,11].

In addition to the above-mentioned risk factors, axial myopia may have also contributed to the development of PAMM in our patient. Many studies have shown that retinal blood flow is reduced in high myopia, which may increase the risk of retinal vasculopathies in such patients [12-14]. One study concluded that retinal blood flow was decreased in high myopia, mainly because of the retinal vessel diameter narrowing [12]. Zheng et al. also demonstrated a reduction in retinal arteriole saturation and narrowing of retinal vessel diameter in highly myopic eyes [14].

To date, there are no treatment modalities for PAMM and management is targeted at treating the underlying cause. In a review by Moura-Coelho et al. The final follow-up visual acuity in patients with PAMM ranged from 20/25 to 20/42 [4]. The visual prognosis is thought to be related to the underlying etiology of PAMM, the severity of the ischemic injury, and the presence of other ocular comorbidities [4].

To conclude, PAMM can develop following intra-ocular surgery and can lead to visual loss of variable severity. The pathophysiology of PAMM is retinal ischemia, but it can occur in healthy young individuals with no vascular risk factors. There is no effective treatment of PAMM although the patient should be investigated for any underlying risk factors.

## References

1. Sarraf D, Rahimy E, Fawzi AA, Sohn E, Barbazetto I, et al. (2013) paracentral acute middle maculopathy: a new variant of acute macular neuroretinopathy associated with retinal capillary ischemia. *jama ophthalmol* 131: 1275-1287.
2. Bernal-Morales C, Velazquez-Villoria D, Cubero-Parra JM, Keane PA, Sim DA, et al. (2022) paracentral acute middle maculopathy after uneventful ocular surgery with local anaesthetic blocks. *eye (lond)* 36: 219-227.
3. Guimarães BF, Damásio MAS, Brina LF, Figueiredo GZC, Houly JR (2023) paracentral acute middle maculopathy in the immediate postoperative of cataract surgery. *arq bras oftalmol* 87: e20210269.
4. Moura-Coelho N, Gaspar T, Ferreira JT, Dutra-Medeiros M, Cunha JP (2020) paracentral acute middle maculopathy-review of the literature. *grafes arch clin exp ophthalmol* 258: 2583-2596.
5. Creese K, Ong D, Sandhu SS, Ware D, Alex Harper C, et al (2017) paracentral acute middle maculopathy as a finding in patients with severe vision loss following phacoemulsification cataract surgery. *clin exp ophthalmol* 45: 598-605.
6. Packer M (2018) the implantable collamer lens with a central port: review of the literature. *clin ophthalmol* 12: 2427-2438.
7. Sander BP (2021) spectral-domain optical coherence tomography in paracentral acute middle maculopathy associated with vasopressor exposure. *clin exp optom* 104: 544-546.
8. Gunay BO (2023) paracentral acute middle maculopathy in a fasting patient after cataract surgery and its response to hyperbaric oxygen therapy. *photodiagnosis photodyn ther* 43: 103714.
9. Nakashima H, Iwama Y, Tanioka K, Emi K (2018) paracentral acute middle maculopathy following vitrectomy for proliferative diabetic retinopathy: incidence, risk factors, and clinical characteristics. *ophthalmology* 125: 1929 -1936.
10. Henein W, Wilson-Pogmore A, Imrie F (2020) a unique case of paracentral acute middle maculopathy with associated cystoid macular oedema post uncomplicated pterygium surgery. *am j ophthalmol case rep* 20:100925.
11. Bernal-Morales C, Velazquez-Villoria D, Cubero-Parra JM, Keane PA, Sim DA, et al. (2022) paracentral acute middle maculopathy after uneventful ocular surgery with local anaesthetic blocks. *eye (lond)* 36: 219-227.
12. Shimada N, Ohno-Matsui K, Harino S, Yoshida T, Yasuzumi K, et al. (2004) reduction of retinal blood flow in high myopia. *grafes arch clin exp ophthalmol* 242: 284-288.

13. Yang Y, Wang J, Jiang H, Yang X, Feng L, et al. (2016) retinal microvasculature alteration in high myopia. *invest ophthalmol vis sci* 57: 6020-6030.
14. Zheng Q, Zong Y, Li L, Huang X, Lin L, et al. (2015) retinal vessel oxygen saturation and vessel diameter in high myopia. *ophthalmic physiol opt* 35: 562-569.